



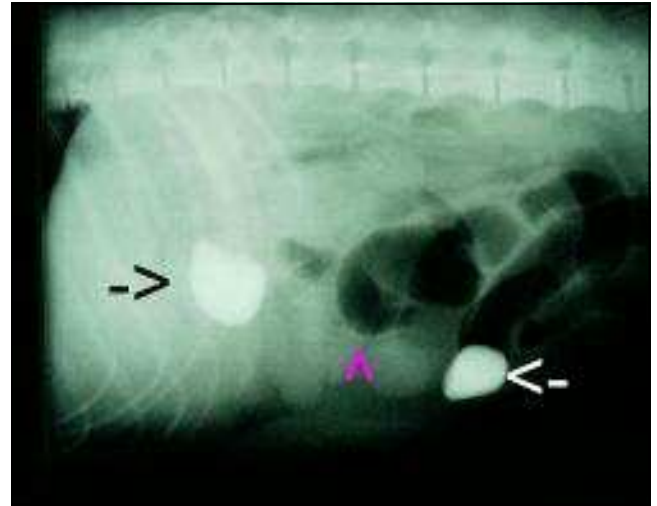
San Carlos Veterinary Hospital (SCVH)
8618 Lake Murray Blvd.
San Diego, CA 92119
(619) 460-3100
www.sancarlosvet.com

- Dr. Dean R. Gahring, D.V.M; Diplomate, ACVS
 - Dr. Bruce N. Persky, D.V.M.
 - Dr. Stanley P. Kus, M.S., D.V.M.
 - Dr. Laurel Nishida, D.V.M.
- E-mail: info@sancarlosvet.com

“Rocksie” - Rock, Gastrointestinal Foreign Bodies



“Rocksie”



X-ray showing rocks in stomach and small intestine.

"Rocksie" is the temporary name we gave this sweet young 9-month-old spayed Lab/Shepherd mix. She was presented for "not feeling well" for about 2 weeks. When the X-rays showed a large rock in the stomach (black arrow) & one in the intestine (white arrow), with dilated, gas-filled intestines (pink arrow) indicating complete obstruction, surgery was strongly recommended.

For whatever reason, the owner did not want to or could not have the surgery performed. We offered to do the surgery if he relinquished the dog to us so we could find a new home for her if she did well with the surgery.

Surgery was performed on an emergency basis: one large rock was removed from the stomach and one was removed from the mid small intestine. There was significant intestinal damage, discoloration, and inflammation.

The day after surgery, "Rocksie" was eating and obviously feeling better. On the third day after surgery, she was doing SO well that she impressed her new owner, who adopted her after just one walk with her in the parking lot!!!



Rocksie's Rocks