



San Carlos Veterinary Hospital (SCVH)
8618 Lake Murray Blvd.
San Diego, CA 92119
(619) 460-3100
www.sancarlosvet.com

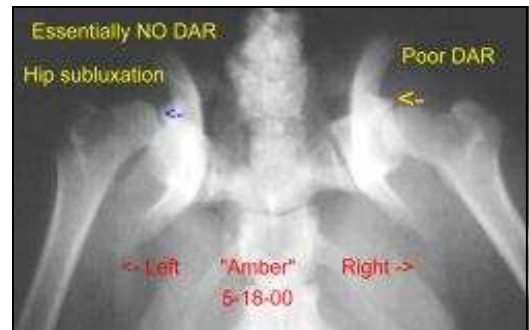- Dr. Dean R. Gahring, D.V.M.; Diplomate, ACVS
 - Dr. Bruce N. Persky, D.V.M.
 - Dr. Stanley P. Kus, M.S., D.V.M.
 - Dr. Laurel Nishida, D.V.M.
- E-mail: info@sancarlosvet.com

“Amber”- DARthroplasty for Hip Dysplasia

Amber is a spayed female Australian shepherd, born in April, 1998. She was diagnosed with bilateral hip dysplasia a year later, in May, 2000. She had marked dorsal subluxation (partial dislocation) of the left hip, a positive Ortolani sign (indicating joint laxity), and crepitus ("crunching and grinding") when the left hip joint was palpated. The right hip dysplasia was not as severe as the left.

Figures 1 and 2, both DAR views ("DAR" stands for Dorsal Acetabular Rim, the upper edge of the hip joint socket), show the severe lack of a DAR in the left hip and a relatively poor one for the right hip. The right femoral head (ball portion of the joint) was sitting in a shallow cup while the left femoral head was riding on a saucer.

A left "standard" DARthroplasty was performed on May 24, 2000. Two corticocancellous bone strips were used to create a new DAR (Figures 3 and 4). Figures 5 and 6 are close-ups of the immediate postoperative left hip, showing the "new DAR" created by the corticocancellous bone strip grafts. These bone grafts eventually anchor to the old DAR via drill holes in the old bone. The graft strips are held in place by sutures through the strips into the joint capsule. The joint capsule eventually becomes the new joint surface.



Figures 1 and 2 (below). X-radiographs on 5/18/00 (left) and 5/24/00, showing no DAR on the left hip and poor DAR on the right hip.

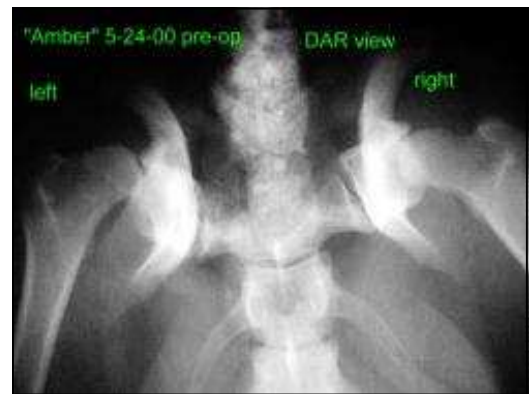

Figure 2

Figure 3

X-radiographs from a ventro-dorsal aspect, showing new DAR created during the DARthroplasty on 5/24/00.

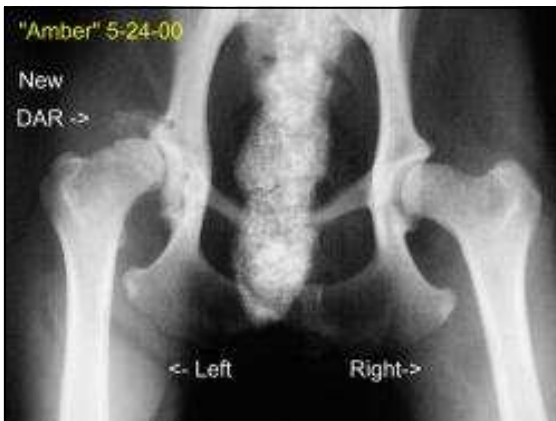
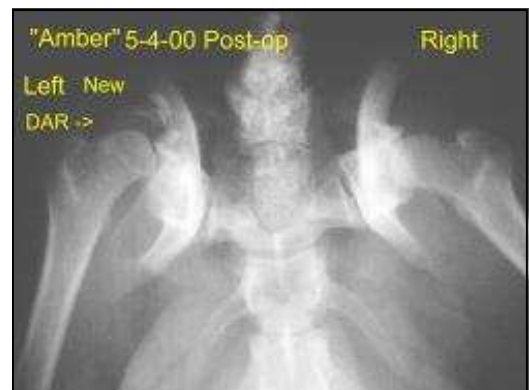
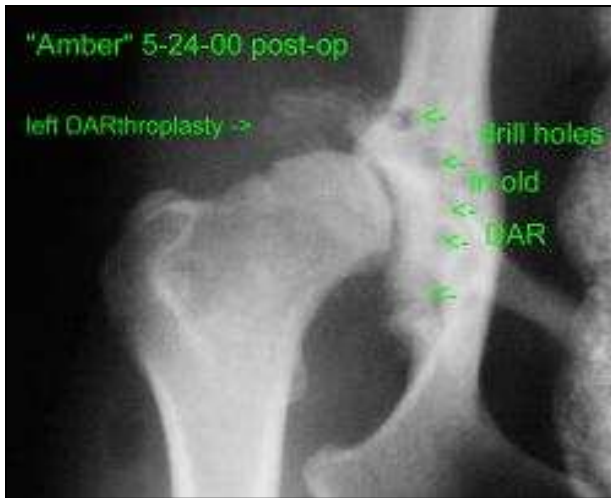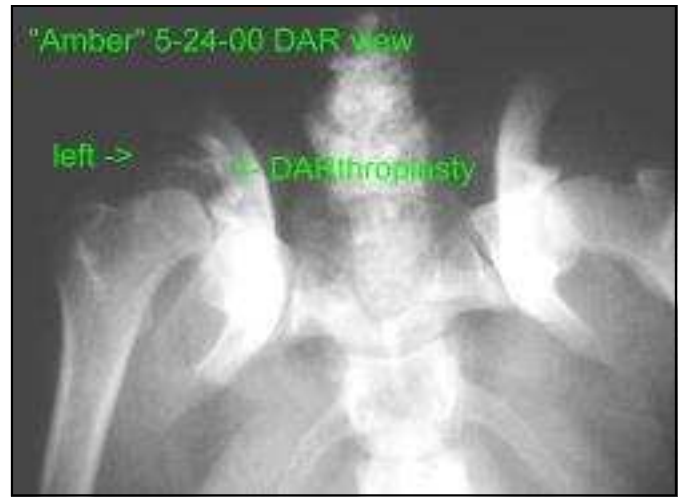Figure 4
X-radiograph from a DAR aspect





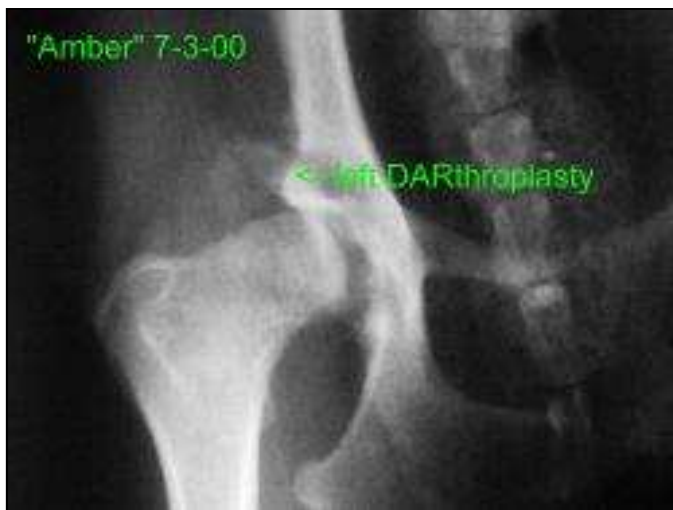Figures 5 and 6.
Close-up X-radiographs of new DAR.



Figures 6.

Our first set of follow-up radiographs were taken on July 3, 2000. At this time, Amber was walking very well on her left rear leg. She also demonstrated an excellent "sit" test. The sit test is an evaluation of how well the dog sits, with the hocks on the ground and the knees pointing straight forward, fully flexed (not extended out to the side, like dogs will sit when their knees or hips bother them).

Figures 7 and 8 show that the left femoral head has started to move slightly more under the old DAR and the new DAR graft is solidifying and consolidating, providing good new bony support for the left femoral head. The joint looks pretty quiet...that is, there is no evidence of any significant progression of degenerative arthritic changes.



Figures 7 & 8. Follow-up X-radiographs on 7/3/00, showing solidification and consolidation of the new DAR.

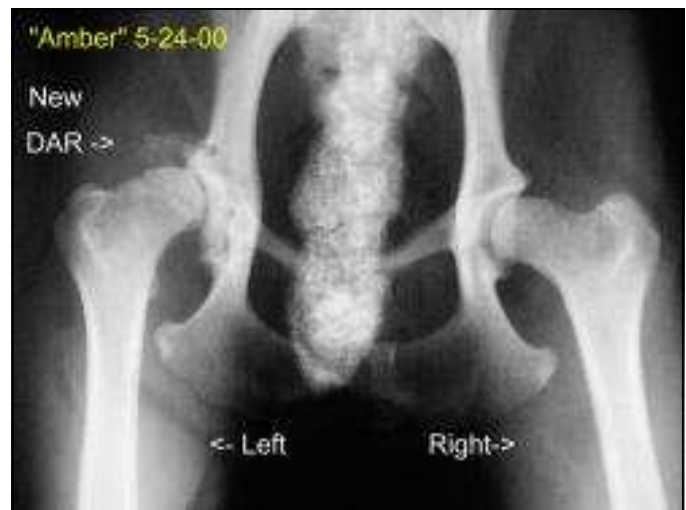

Figure 8.



"Amber" cont.



On October 3, 2000, a right "minor" DARthroplasty was performed, utilizing only one corticocancellous strip graft (Figures 9-12). Figures 13 and 14 show Amber immediately after her right hip surgery, already putting weight on the leg! This is typical with the DARthroplasty surgery. Amber continues to progress very well and is using both rear legs actively at this time.

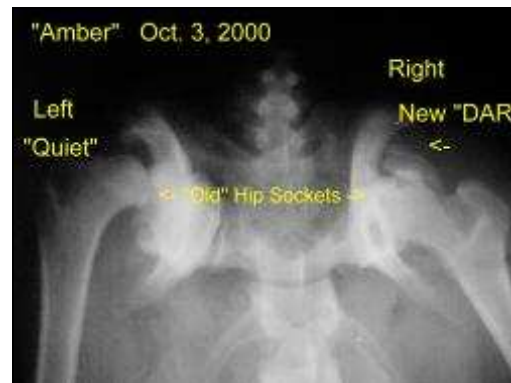

Figure 9
DAR view of Amber's right hip after "minor" DARthroplasty on 10/3/00.

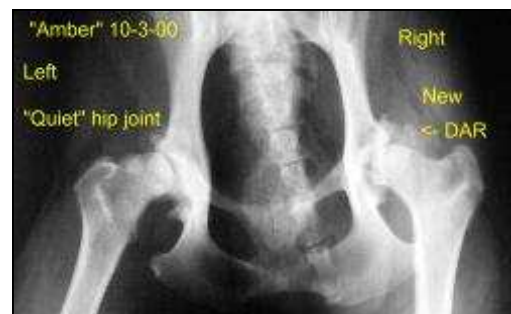

Figure 10
DAR ventrodorsal view of Amber's right hip.

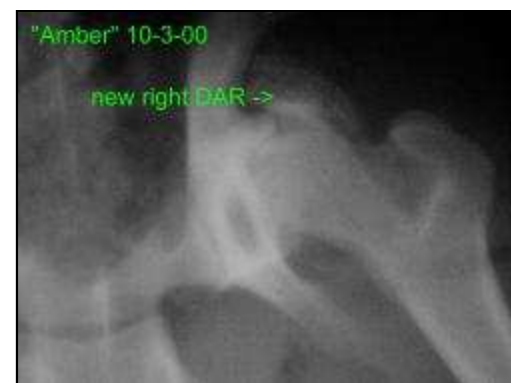


Figure 11
Close-up X-radiograph of right hip

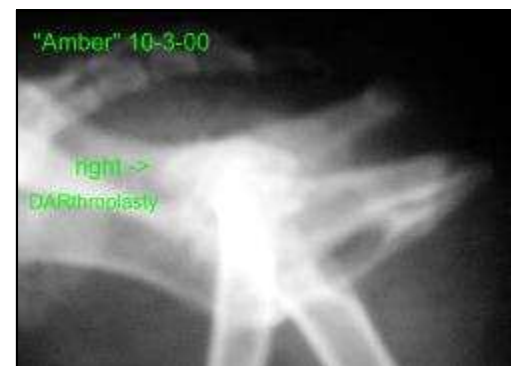
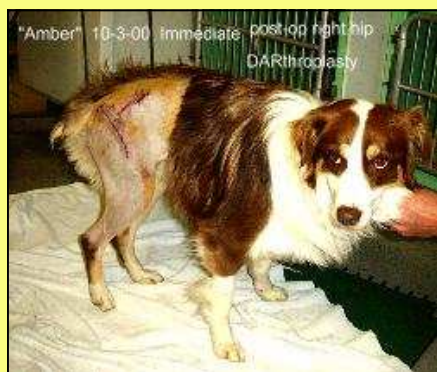
Figure 12
X-radiograph of right hip DARthroplasty.

Amber After Surgery

In April 2001, Amber's owners sent along some follow-up photos (Figures 15 & 16) with a nice note:

"Amber is quite happy and leads a very normal dog's life, along with our other Aussie, Hubie... Again I say, please use Amber as a perfect example of how good this surgery is."



Figures 13 and 14.
Amber immediately postoperative. Note that she is already putting weight on the right-rear leg that had just been operated on.

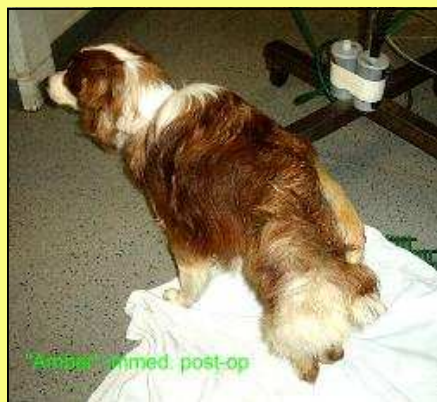

Figure 14.



Figure 15
Amber April, 2001. Inside on a rainy day.



Figure 16
Sitting pretty on the patio.