



San Carlos Veterinary Hospital (SCVH)
8618 Lake Murray Blvd.
San Diego, CA 92119
(619) 460-3100
www.sancarlosvet.com

- Dr. Dean R. Gahring, D.V.M; Diplomate, ACVS
 - Dr. Bruce N. Persky, D.V.M.
 - Dr. Stanley P. Kus, M.S., D.V.M.
 - Dr. Laurel Nishida, D.V.M.
- E-mail: info@sancarlosvet.com

“April” - Pyometra

"April" was presented as an 11-year-old unspayed female Sheltie with a history of weight loss, decreased appetite, and squinting eyes. She had been "in heat" about a week prior to presentation.

Physical examination revealed a small amount of mucopurulent (pus with mucus) vaginal discharge and anterior uveitis (inflammation of the front chamber of the eyes) of both eyes. Her body temperature was high normal.

Our work-up included a blood panel and abdominal radiographs. Her CBC (complete blood count) and chemistries were normal, but radiographs of the abdomen (Figure 1)

showed a markedly enlarged uterus (the uterus is not seen on radiographs if it is normal size).

April was taken to surgery for a suspected pyometra. Pyometra is a condition whereby the uterus, due to an imbalance of hormones from the ovaries, fills with pus. Surgery confirmed the diagnosis, and April was spayed...the enlarged, pus-filled uterus and both ovaries were removed. She recovered nicely from surgery and was eating normally the next day. Her anterior uveitis had almost completely resolved as well, thus confirming that the uveitis was apparently caused by the pyometra.

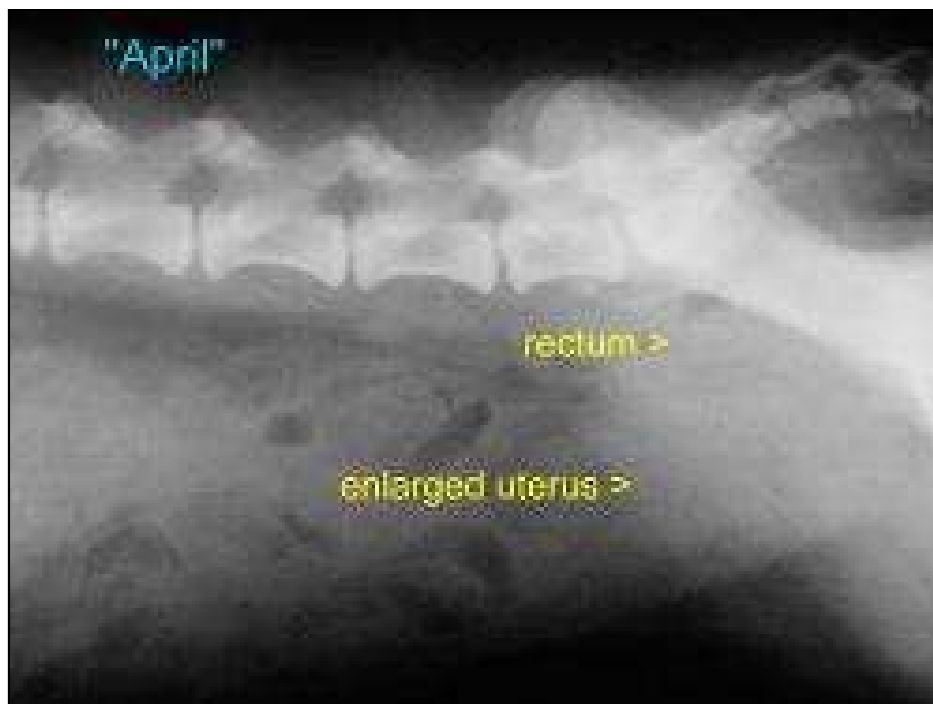


Figure 1. Radiograph showing enlarged uterus