



San Carlos Veterinary Hospital (SCVH)
8618 Lake Murray Blvd.
San Diego, CA 92119
(619) 460-3100
www.sancarlosvet.com

- Dr. Dean R. Gahring, D.V.M; Diplomate, ACVS
 - Dr. Bruce N. Persky, D.V.M.
 - Dr. Stanley P. Kus, M.S., D.V.M.
 - Dr. Laurel Nishida, D.V.M.
- E-mail: info@sancarlosvet.com

“Foggie” - Lung Lobectomy for Cancer in Cat

Foggie is a beautiful fifteen-year-old gray neutered male cat. He was presented after coughing for several weeks. Since the cough was not severe, we assumed that Foggie may have the beginnings of feline asthma. Further tests were not pursued at that time.

Eight months later, Foggie was presented to the hospital for dental cleaning and polishing and to explore the throat under general anesthesia. Foggie had developed a deep, persistent cough (especially at night) and had some trouble swallowing. The oral exam was negative. However, chest x-rays revealed a very dense right accessory lung lobe. Cytology from a fine needle aspirate of the lung lobe was inconclusive. Foggie was put on antibiotics in hopes this was a lobar pneumonia.

When the antibiotics did not result in any significant improvement, Foggie was scheduled for surgery to remove the consolidated lung lobe. A right lateral thoracotomy was performed at the sixth intercostal rib space (between the 6th and 7th ribs) and the right accessory lung lobe was removed.

After five or six rough postoperative days, Foggie began to eat again. The biopsy report came back with a diagnosis of intermediate- to high-grade bronchogenic pulmonary adenocarcinoma, a form of lung cancer. There were no other signs of the tumor in

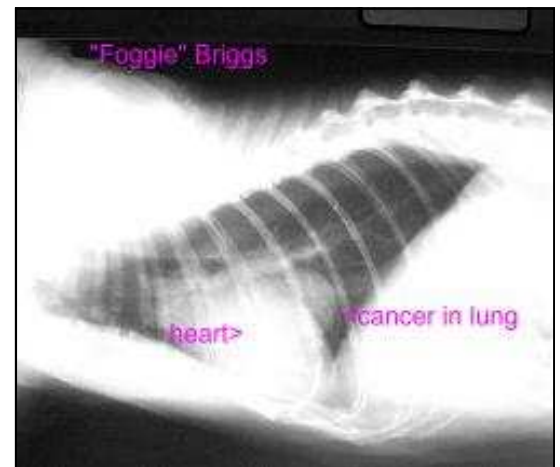


Figure 2. Ventrodorsal view of Foggie's lung cancer.

the lungs or regional lymph nodes, which is a good sign for this handsome senior citizen.

The picture below shows Foggie about three weeks after surgery. At this point he was still a little "under the weather." But eventually, Foggie did great. He began acting like a 10 year old instead of a 15 year old!

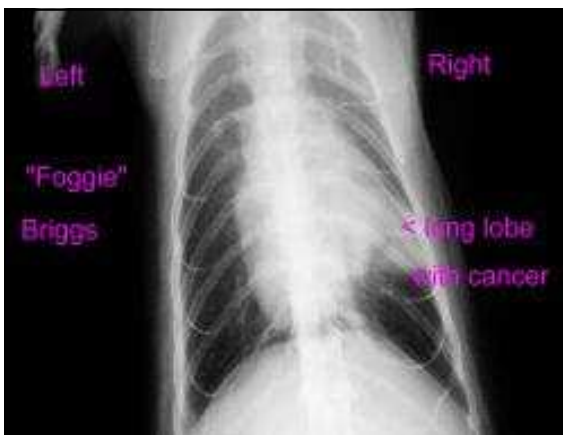
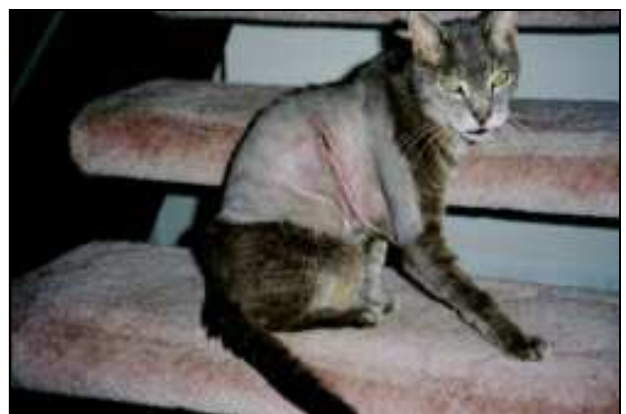
Figure 1. Lateral view showing cancer in Foggie's right lung.



Foggie, three weeks post-op.